



The Distribution of Matrix Metalloproteinase-2, Tissue Inhibitor of Metalloproteinase-2 and Tissue Inhibitor of Metalloproteinase-4 in Psoriatic Skin

Elga Sidhom^{1*}, Mara Pilmane¹ and Janis Kisis²

¹Institute of Anatomy and Anthropology, Rīga Stradiņš University, Kronvalda bulv 9, Rīga, LV-1010, Latvia.

²Department of Infectology and Dermatology, Rīga Stradiņš University, A. Briāna iela 2, Rīga, LV-1001, Latvia.

Authors' contributions

This work was carried out in collaboration between all authors. Author ES managed the literature searches, performed the immunohistochemical and statistical analysis, and wrote the first draft of the manuscript. Author MP designed the study and wrote the protocol. Author JK managed the analyses of the study. All authors read and approved the final manuscript.

Article Information

DOI: 10.9734/BJMMR/2015/18206

Editor(s):

(1) C. Cameron Yin, Department of Hematopathology, UTMD Anderson Cancer Center, Houston, TX, USA.

Reviewers:

(1) Anonymous, Greece.

(2) Mutlu Çayırılı, Department of Dermatology, Mevki Military Hospital, Turkey.

(3) Anonymous, USA.

(4) Anonymous, Wrocław Medical University, Poland.

Complete Peer review History: <http://www.sciencedomain.org/review-history.php?iid=1122&id=12&aid=9506>

Short Research Article

Received 9th April 2015
Accepted 5th May 2015
Published 30th May 2015

ABSTRACT

Aims: To evaluate the appearance and distribution of matrix metalloproteinase-2 (MMP-2), tissue inhibitor of metalloproteinase-2 (TIMP-2) and tissue inhibitor of metalloproteinase-4 (TIMP-4) in lesional skin biopsies of psoriasis patients.

Study Design: Observational study.

Place and Duration of Study: Institute of Anatomy and Anthropology and Department of Infectology and Dermatology, Rīga Stradiņš University, between September 2013 and June 2014.

Methodology: We included 40 patients (31 men, 9 women; age range 18-70 years) with *Psoriasis vulgaris*, with present characteristic psoriatic eruptions in typical localization sites and no treatment received. Skin samples were obtained using routine punch biopsy method. 10 clinically healthy skin samples obtained during nevus excision procedure were used as control material. All

*Corresponding author: Email: dr.elgasidhom@yahoo.com;

tissue specimens were stained with hematoxylin and eosin and by immunohistochemistry for MMP-2, TIMP-2 and TIMP-4. The intensity of staining was graded semiquantitatively. Spearman's rank correlation coefficient was calculated.

Results: In psoriasis patients numerous MMP-2-containing keratinocytes were found in epidermis, MMP-2 positive dermal fibroblasts and inflammatory cells varied from few to abundant. Few epidermal cells and moderate to numerous dermal cells contained TIMP-2. Moderate to numerous epidermal and dermal cells contained TIMP-4. Statistically significant strong positive correlation was found between MMP-2 in epidermis and dermis (Spearman's rank correlation coefficient = .878, $P = .000$). Statistically significant moderate positive correlation was found between TIMP-2 and TIMP-4 in dermis (Spearman's rank correlation coefficient = .639, $P = .000$) and between TIMP-2 in epidermis and dermis (Spearman's rank correlation coefficient = .564, $P = .000$).

Conclusion: TIMP-4 seems to be most important inhibitor of psoriatic skin degeneration, richly raised by MMP-2. Its moderate correlation with TIMP-2 proves involvement of other tissue inhibitors in the degeneration inhibition and gives evidence about possible patterning between the tissue inhibitors of metalloproteinases.

Keywords: Matrix metalloproteinase; endopeptidase; tissue inhibitor of metalloproteinase; psoriasis.

1. INTRODUCTION

Psoriasis is common chronic inflammatory skin condition associated with significant comorbidities [1]. Genetic and immunologic studies suggest psoriasis is a T helper 1-type disease. The knowledge about the involvement and role of matrix metalloproteinases (MMPs) and their tissue inhibitors (TIMPs) in psoriatic inflammation is limited. Endogenous and exogenous proteases (cathepsins, caspases, kallikreins, matriptase) are able to target defense molecules in epidermis. At the same time their inhibitors maintain the integrity and protective barrier of human skin, and it is therefore speculated that a misbalance can result in inflammation [2].

The matrix metalloproteinase (MMP) family consists of a number of Zinc-dependent proteolytic enzymes. MMPs take part in the normal development of the skin, but healthy skin does not constitutively express MMPs. In contrast, MMP-1, MMP-2, MMP-3, MMP-7, MMP-8, MMP-9, MMP-12 and membrane type 1-matrix metalloproteinase (MT1-MMP) degrade extracellular matrix in arthritis, hypertension, and cardiac disease [3]. Excessive MMPs activity has been found in chronic wounds and impaired wound healing [4,5].

MMPs expression in skin is regulated by cytokines, growth factors and also the presence of tissue inhibitors of metalloproteinases. These inhibitors may be multifunctional and can directly regulate cell growth and apoptosis. TIMPs have also shown the ability to regulate MMPs activity, as unregulated MMPs possibly result in tissue damage [6].

Therefore, we suggest that MMPs and TIMPs could be of importance in the pathogenesis of psoriasis and should be explored as possible biomarkers. The aim of the study was to evaluate the appearance and distribution of matrix metalloproteinase-2 (MMP-2), tissue inhibitor of metalloproteinase-2 (TIMP-2) and tissue inhibitor of metalloproteinase-4 (TIMP-4) in lesional skin biopsies of psoriasis patients.

2. METHODOLOGY

Forty *Psoriasis vulgaris* patients between the age of 18 and 70 (31 men, 9 women) were selected. Patients had at least a six weeks history of characteristic psoriatic eruptions in typical localization sites. Patients with systemic comorbidities were excluded. Skin biopsies were obtained from new untreated psoriasis lesions using routine 3 mm punch biopsy under local infiltrative anesthesia using 2% lidocaine, maintaining an aseptic technique. Non-lesional skin was not studied. Ten clinically healthy skin samples obtained during nevus excision procedure were used as control material.

Skin biopsy tissue was fixed in Stefanini's solution [7], dehydrated and embedded in paraffin. Further four micrometers thick sections were prepared and stained routinely with hematoxylin and eosin [8].

2.1 Histology

Immunohistochemistry (IMH): MMP-2 (Cat No AF902, Lot No DUB03, obtained from goat, 1:100 dilution, R&D Systems, Germany), TIMP-2 (3A4: sc-21735, obtained from mouse, 1:50 dilution, Santa Cruz Biotechnology, Inc., USA) and TIMP-4 (Cat No orb106543, obtained from

rabbit, 1:50 dilution, Biorbyt Limited, Cambridge, UK) were used by biotin – streptavidin IMH [9].

Skin biopsy tissue was deparaffinized and washed in alcohol and water, then washed for 10 minutes in wash buffer (Tris-buffered saline) and put for 5 minutes in EDTA boiling buffer in microwave. When the samples had cooled down, they were washed twice for 5 minutes in wash buffer. To decrease background staining normal blocking serum for 20 minutes was used. All skin tissue samples were incubated with primary antibodies for 1 hour. Further, washing for 10 minutes in wash buffer and incubation for 30 minutes with LSAB+LINK with biotin related secondary antibodies (code K1015, DakoCytomation, Denmark) was performed. Another washing for 5 minutes in wash buffer was performed. Skin biopsies were incubated for 25 minutes with LSAB+LINK with enzyme peroxidase labeled streptavidine (code K0690, DakoCytomation, Denmark). It was followed by 5 minutes washing in wash buffer and 10 minutes processing with DAB substrate-chromogen system (code K3468, DakoCytomation, Denmark) to obtain positive structure staining in brown colour. Samples were then rinsed in running water and stained with hematoxylin.

Findings were evaluated using Leica DC 300F camera and image processing and analysis software Image Pro Plus.

The intensity of immunostaining was graded semiquantitatively:

- Few positive structures in the visual field were labeled with +,
- Moderate number of positive structures in the visual field was labeled with ++,
- Numerous positive structures in the visual field were labeled with +++,
- Abundance of positive structures in the visual field was marked with ++++ [10].

To obtain statistical data we used non-parametric statistics – Spearman's rank correlation coefficient was calculated [11].

3. RESULTS

3.1 Morphology

In all 10 skin samples obtained from control patients we found practically unchanged histological picture.

Lesional epidermis of psoriasis patients was characterized by excess proliferation of basal layer, prominent reduction of granular layer, parakeratosis. Inflammatory infiltration presented diffusive character predominantly patchy in papillary dermis, especially perivascularly to arterioles. We detected presence of numerous epitheloid cells and macrophages, as well as Munro microabscesses. Inflammatory cells (lymphocytes and macrophages mainly) were found also surrounding hair follicles and eccrine sweat glands. Eccrine sweat glands presented vacuolization.

3.2 Immunohistochemistry

MMP-2 expressed in few to moderate (+/++) keratinocytes and in moderate to numerous (+/+++) dermal connective tissue cells in healthy skin (Fig. 1). In tissue samples of psoriasis patients numerous (+++) MMP-2-containing keratinocytes were found in basal and spinous layers (Stratum germinativum) of epidermis, while granular layer in many skin samples simultaneously was lacking any MMP-2 positive cells. MMP-2 positive dermal fibroblasts and inflammatory cells (macrophages and lymphocytes) mainly in papillary layer varied from few (+) to abundant (+++++) (Fig. 2). MMP-2-containing cells were found also in sebaceous and eccrine sweat glands, hair follicles and walls of blood vessels.

In control skin tissue samples numerous (+++) keratinocytes contained TIMP-2, while only moderate (++) TIMP-2-containing connective tissue cells were found in dermis (Fig. 3). Psoriatic lesions presented with few (+) epidermal keratinocytes mostly in basal layer containing TIMP-2, meanwhile TIMP-2-containing fibroblasts, macrophages and lymphocytes in dermis varied mainly from moderate (++) to numerous (+++) (Fig. 4). Very few eccrine sweat glands, hair follicles and blood vessels had traces of TIMP-2 presence.

Numerous (+++) TIMP-4-containing keratinocytes were found in epidermis of healthy skin, while dermis presented with moderate to numerous (+/+++) TIMP-4-containing fibroblasts (Fig. 5). Moderate (++) to numerous (+++) epidermal keratinocytes and fibroblasts, as well as macrophages and lymphocytes in dermis contained TIMP-4 in tissue samples of psoriasis lesions (Fig. 6). In epidermis the presence of TIMP-4 positive cells was patchy.

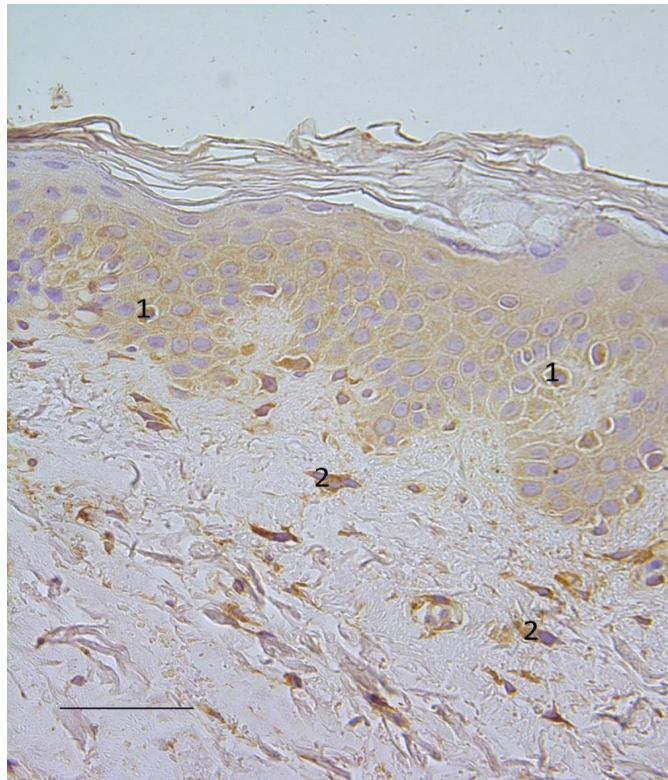


Fig. 1. Few MMP-2 containing keratinocytes (1) and moderate MMP-2 positive dermal connective tissue cells (2) in healthy skin. MMP-2 IMH, X 400, scale bar: 3.3 μ m

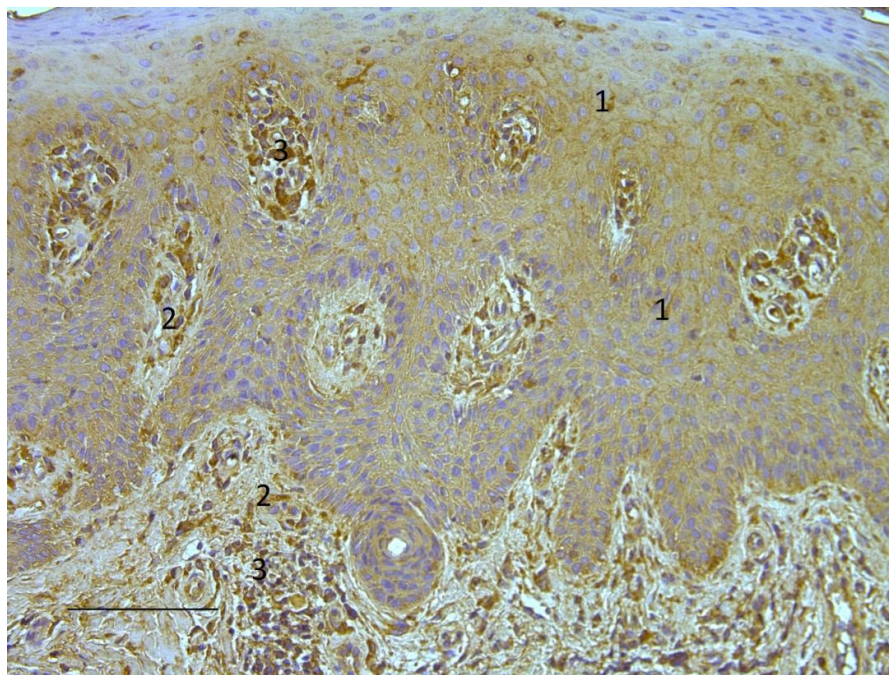


Fig. 2. Abundance of MMP-2-containing keratinocytes (1) in epidermis and fibroblasts (2) and inflammatory cells (3) in dermis of psoriatic skin. MMP-2 IMH, X 200, scale bar: 7.25 μ m

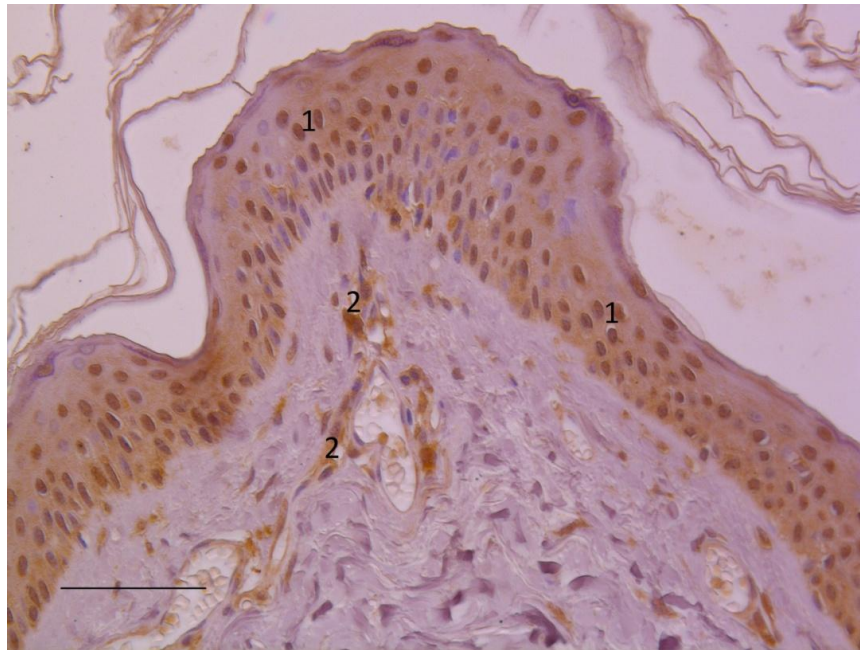


Fig. 3. Numerous epidermal keratinocytes (1) and moderate connective tissue cells (2) containing TIMP-2 in dermis of healthy skin. TIMP-2, X 400, scale bar: 3.6 μ m

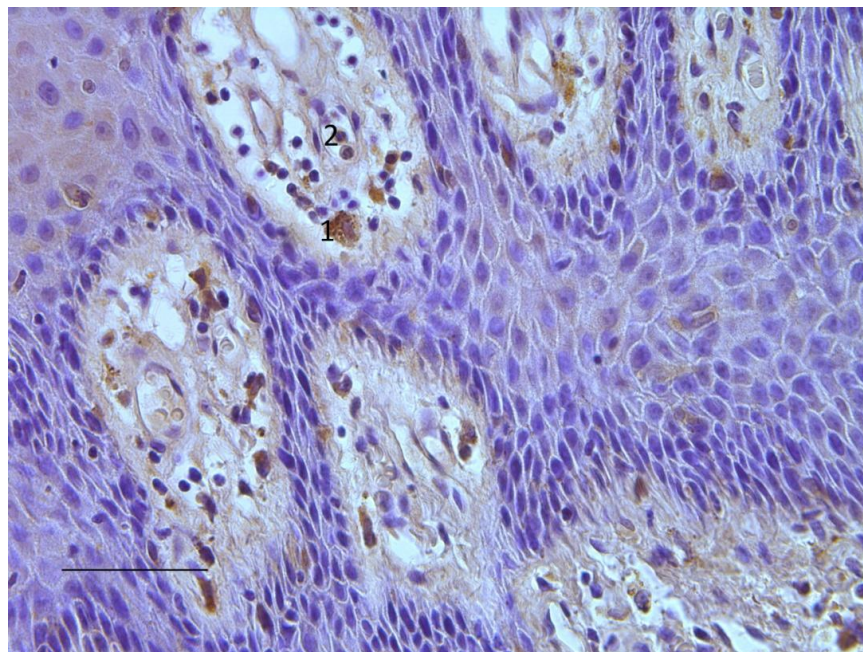


Fig. 4. Numerous TIMP-2 positive macrophages (1) and lymphocytes (2) particularly in psoriasis affected papillary dermis. TIMP-2 IMH, X 400, scale bar: 3.6 μ m

Numerous TIMP-4 containing cells of sebaceous glands and eccrine sweat glands, hair follicles and blood vessels were found.

Statistically significant difference between patients with psoriasis and control patients was found for TIMP-2 and TIMP-4 factors in epidermis.

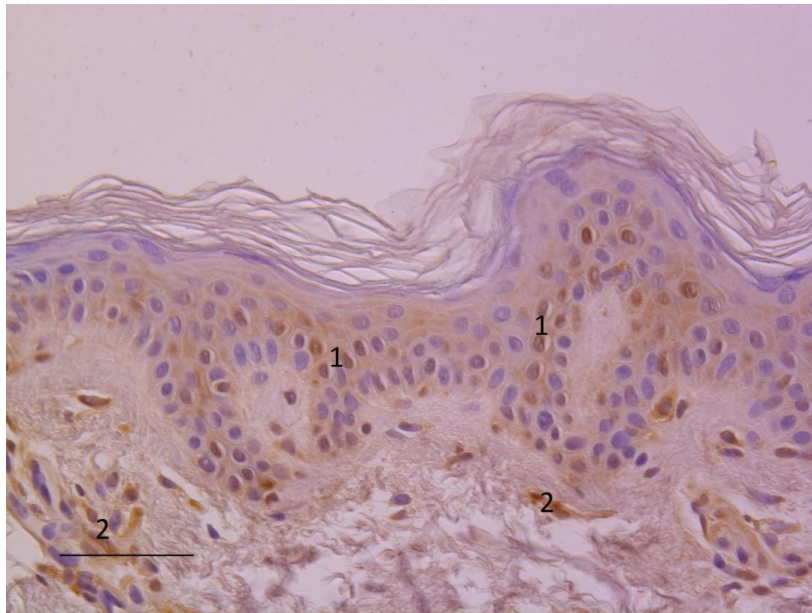


Fig. 5. Numerous TIMP-4-containing keratinocytes (1) in epidermis and moderate TIMP-4-containing fibroblasts (2) in dermis of healthy skin. TIMP-4 IMH, X 400, scale bar: 3.6 μ m

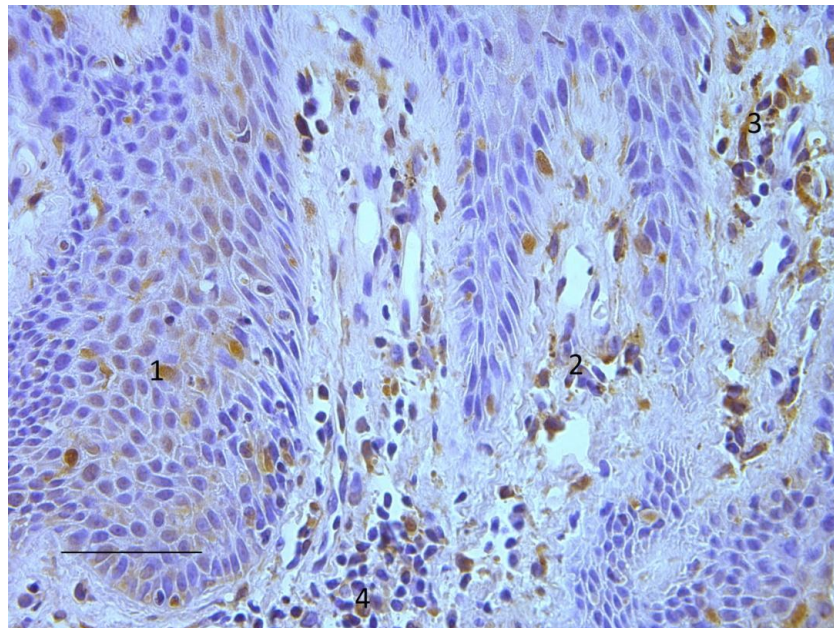


Fig. 6. Numerous TIMP-4 positive keratinocytes (1) and dermal fibroblasts (2), as well as macrophages (3) and lymphocytes (4) in psoriatic skin. TIMP-4 IMH, X 400, scale bar: 3.6 μ m

In psoriasis patients statistically significant strong positive correlation was found between MMP-2 in epidermis and dermis (Spearman's rank correlation coefficient = .878, $P = .000$) and statistically significant moderate positive correlation was found between TIMP-2 and

TIMP-4 in dermis (Spearman's rank correlation coefficient = .639, $P = .000$), and between TIMP-2 in epidermis and dermis (Spearman's rank correlation coefficient = .564, $P = .000$). Also in psoriasis patients statistically significant weak positive correlation was found between TIMP-4 in

epidermis and dermis (Spearman's rank correlation coefficient = .485, $P = .002$) and between MMP-2 in epidermis and TIMP-2 in epidermis (Spearman's rank correlation coefficient = .377, $P = .017$).

4. DISCUSSION

We found increased expression of MMP-2 in psoriatic epidermis, epidermal appendages and dermis. This is in agreement with previous studies of MMP-2 in psoriasis patients with a history of diabetes and allergy compared to patients with psoriasis only [12,13]. Thus, our data of MMP-2 presence in psoriatic skin suggests a more general MMP-2 upregulation. In a previous immunohistochemical study, MMP-2 and MMP-9 were seen to be upregulated in psoriatic skin compared to healthy skin, while TIMP-1 and TIMP-2 expression decreased [14]. While TIMP-1 appeared immunohistochemically decreased in psoriatic lesions, data on MMP-12, MMP-9, TIMP-1 and TIMP-3 obtained by mRNA imply increases of MMPs and TIMP-1 in psoriatic dermal infiltrates [15]. We also found more decreased expression of TIMP-2 in psoriatic epidermis while dermal cells presented with moderate amount of TIMP-2 positive cells possibly suggesting a compensatory mechanism.

To our knowledge no studies have looked at the presence or absence of TIMP-4 in psoriatic lesions. We found abundant TIMP-4-containing cells in dermal infiltrates, as well as epidermal keratinocytes expressed TIMP-4. Expression of TIMP-2 and TIMP-4 in psoriatic dermis showed positive correlation and can be hypothesised as a pattern of compensatory inhibitory factors possibly associated with psoriasis.

MMPs and their inhibitors have also been studied in the serum of psoriasis and psoriatic arthritis patients. It has been suggested that plasma transforming growth factor-beta1, TIMP-1, MMP-1 and interleukin-18 could be used as combined biomarker of psoriasis activity [16]. Plasma MMP-3 together with high-sensitivity C-reactive protein might help to differentiate psoriatic disease alone from psoriasis together with psoriatic arthritis [17]. Changes in plasma concentrations of MMP-1 and TIMP-1 levels in psoriasis patients have been detected as a response to topical psoriasis treatment [18]. The data are compatible with decreased epidermal regulation of MMP-2 and a compensatory increase in dermal TIMP

expression. In contrast to the increased expression of MMP-2, the observations imply that the role and expression of TIMP is controversial and can show differences between gene involvement and tissue findings. We suggest that an MMP-2 increase along to TIMP-2 and TIMP-4 correlative changes could serve as tissue biopattern for the psoriasis, suggesting a role for tissue TIMPs in psoriasis.

5. CONCLUSION

TIMP-4 seems to be most important inhibitor of psoriatic skin degeneration, richly raised by MMP-2. Its moderate correlation with TIMP-2 proves involvement of other tissue inhibitors in the degeneration inhibition and gives evidence about possible patterning between the tissue inhibitors of metalloproteinases.

CONSENT

It is not applicable.

ETHICAL APPROVAL

All authors hereby declare that all experiments have been examined and approved by the appropriate ethics committee and have therefore been performed in accordance with the ethical standards laid down in the 1964 Declaration of Helsinki.

The study was approved by the Ethical Committee at Rīga Stradiņš University, permit issued on September 10, 2009.

ACKNOWLEDGEMENTS

“Support for Doctoral Students in Mastering the Study Programme and Acquisition of a Scientific Degree in Rīga Stradiņš University”, agreement No 2009/0147/1DP/1.1.2.1.2/09/IPA/VIAA/009.

COMPETING INTERESTS

Authors have declared that no competing interests exist.

REFERENCES

1. Miller IM, Ellervik C, Zarchi KS, Ibler KS, Vinding GR, Knudsen KM, et al. The association of metabolic syndrome and psoriasis: A population- and hospital-based

- cross-sectional study. *J Eur Acad Dermatol Venereol.* 2015;29(3):490-7. (DOI: 10.1111/jdv.12595)
2. Meyer-Hoffert U. Reddish, scaly, and itchy: how proteases and their inhibitors contribute to inflammatory skin diseases. *Arch Immunol Ther Exp (Warsz).* 2009;57(5):345-54. (DOI: 10.1007/s00005-009-0045-6)
 3. Chen Q, Jin M, Yang F, Zhu J, Xiao Q, Zhang L. Matrix metalloproteinases: Inflammatory regulators of cell behaviors in vascular formation and remodeling. *Mediators Inflamm.* 2013;928315. DOI: 10.1155/2013/928315
 4. Raza SL, Cornelius LA. Matrix metalloproteinases: Pro- and anti-angiogenic activities. *J Investig Dermatol Symp Proc.* 2000;5(1):47-54.
 5. Xue M, Le NT, Jackson CJ. Targeting matrix metalloproteases to improve cutaneous wound healing. *Expert Opin Ther Targets.* 2006;10(1):143-55. (DOI: 10.1517/14728222.10.1.143)
 6. Stetler-Stevenson WG. Tissue inhibitors of metalloproteinases in cell signaling: Metalloproteinase-independent biological activities. *Sci Signal.* 2008;1(27):re6. (DOI: 10.1126/scisignal.127re6)
 7. Stefanini M, De Martino C, Zamboni L. Fixation of ejaculated spermatozoa for electron microscopy. *Nature.* 1967;216(5111):173-4.
 8. Fischer AH, Jacobson KA, Rose J, Zeller R. Hematoxylin and eosin staining of tissue and cell sections. *CSH Protoc.* 2008; pdb.prot4986. (DOI: 10.1101/pdb.prot4986)
 9. Hsu SM, Raine L, Fanger H. The use of antiavidin antibody and avidin-biotin peroxidase complex in immunoperoxidase technics. *Am J Clin Pathol.* 1981;75(6): 816-21.
 10. Pilmane M, Luts A, Sundler F. Changes in neuroendocrine elements in bronchial mucosa in chronic lung disease in adults. *Thorax.* 1995;50(5):551-4.
 11. Christensen R. *Analysis of Variance, Design and Regression: Applied Statistical Methods.* London: Chapman & Hall; 1996.
 12. Lee SE, Lew W. The Increased Expression of Matrix-Metalloproteinase-9 Messenger RNA in Non-lesional Skin of Patients with Large Plaque Psoriasis Vulgaris. *Ann Dermatol.* 2009;21(1):27-34. (DOI: 10.5021/ad.2009.21.1.27)
 13. Vasku V, BienertovaVasku J, Slonková V, Kanková K, Vasku A. Matrix metalloproteinase-2 promoter variability in psoriasis. *Arch Dermatol Res.* 2009;301(6):467-73. (DOI: 10.1007/s00403-009-0947-5)
 14. Simonetti O, Lucarini G, Goteri G, Zizzi A, Biagini G, Lo Muzio L et al. VEGF is likely a key factor in the link between inflammation and angiogenesis in psoriasis: Results of an immunohistochemical study. *Int J Immunopathol Pharmacol.* 2006;19(4): 751-60.
 15. Suomela S, Kariniemi AL, Snellman E, Saarialho-Kere U. Metalloelastase (MMP-12) and 92-kDa gelatinase (MMP-9) as well as their inhibitors, TIMP-1 and -3, are expressed in psoriatic lesions. *Exp Dermatol.* 2001;10(3):175-83. (DOI: 10.1034/j.1600-0625.2001.010003175.x)
 16. Flisiak I, Zaniewski P, Chodyncka B. Plasma TGF-beta1, TIMP-1, MMP-1 and IL-18 as a combined biomarker of psoriasis activity. *Biomarkers.* 2008;13(5):549-56.
 17. Chandran V. Soluble biomarkers may differentiate psoriasis from psoriatic arthritis. *J Rheumatol Suppl.* 2012;89:65-6. (DOI: 10.3899/jrheum.120247)
 18. Flisiak I, Mysliwiec H, Chodyncka B. Effect of psoriasis treatment on plasma concentrations of metalloproteinase-1 and tissue inhibitor of metalloproteinases-1. *J Eur Acad Dermatol Venereol.* 2005;19(4): 418-21. (DOI: 10.1111/j.1468-3083.2005.01199.x)

© 2015 Sidhom et al.; This is an Open Access article distributed under the terms of the Creative Commons Attribution License (<http://creativecommons.org/licenses/by/4.0>), which permits unrestricted use, distribution, and reproduction in any medium, provided the original work is properly cited.

Peer-review history:

The peer review history for this paper can be accessed here:
<http://www.sciencedomain.org/review-history.php?iid=1122&id=12&aid=9506>