



## **Cerebral Cortical Damage in Adult Wistar Rats Following Aluminium Chloride Administration**

**A. J. Ajibade<sup>1\*</sup>, P. B. Fakunle<sup>1</sup> and O. O. Omoola<sup>1</sup>**

<sup>1</sup>*Department of Anatomy, Ladoké Akintola University of Technology (LAUTECH), Ogbomoso, Nigeria.*

### **Authors' contributions**

*This work was carried out in collaboration among all authors. Author AJA designed the study, performed the statistical analysis, author PBF wrote the protocol and wrote the first draft of the manuscript and author OOO managed the analyses and the literature searches of the study. All authors read and approved the final manuscript.*

### **Article Information**

DOI: 10.9734/AJRIMPS/2019/v7i330121

#### Editor(s):

(1) Dr. Lokendra Bahadur Sapkota, Assistant Professor, Department of Biochemistry, Chitwan Medical College, Bharatpur, Nepal.

#### Reviewers:

- (1) Ayobola Abolape Iyanda, Ladoké Akintola University of Technology, Nigeria.  
(2) Euclides Mauricio Trindade Filho, State University of Health Sciences of Alagoas, Brazil.  
(3) Alok Nahata, Ying Zhi Agricultural and Industries, Malaysia.

Complete Peer review History: <http://www.sdiarticle3.com/review-history/49605>

**Original Research Article**

**Received 14 April 2019**  
**Accepted 27 June 2019**  
**Published 04 July 2019**

### **ABSTRACT**

This study investigated some effects of aluminium chloride on the cerebral cortex of adult Wistar rats. Aluminium chloride as one of the toxic metals has been known to be one of the major environmental pollutants across the world which has been reported in relation to Neurodegenerative diseases (ND) associated with metallic intoxication. It is present in many pharmaceutical drugs, food products and also used in the treatment of domestic water being involved in skeletal, haematological and neurological diseases.

Thirty-two adult Wistar of both sexes weighing between 143 g-189 g were randomly grouped into four groups, group A, B, C and D each group containing 8 rats. Group A rats which were the controls, were maintained on standard feed (grower mash) and water for 21 days. Rats in group B, C and D were treated with 0.2 g/kg, 0.4 g/kg and 0.6 g/kg of aluminium chloride respectively for 21 days. The aluminium chloride solution was administered orally on a daily basis for that period.

The weight of the Wistar rats was recorded on a weekly basis (before and at the end of each week of administration). On the 22nd day the Wistar rats in group A, B, C and D were sacrificed by

\*Corresponding author: E-mail: [adeshinaajibade@yahoo.co.uk](mailto:adeshinaajibade@yahoo.co.uk);

cervical dislocation, blood was collected through cardiac puncture, the brain was removed and weighed immediately using sensitive balance, part of the brain of all Wistar rats in each group was collected and homogenized for biochemical analysis, the remaining part was then fixed in 10% formal saline, the tissue was processed and sectioned at 5µm and stained with hematoxylin and eosin for histological study.

Results showed that the mean body weights of the Wistar rats significantly increased in the treated groups when compared with the control group. The mean brain weights of the aluminium- treated groups showed insignificant decreased ( $P>0.05$ ) when compared to the control group. In the biochemical analysis, there was a statistically significant increase ( $P<0.05$ ) in the level of Malondialdehyde (MDA) in the aluminium-treated groups, and a significant decrease ( $P<0.05$ ) in the level of Superoxide dismutase (SOD), and Succinate Dehydrogenase (SDH) in the aluminium treated group. Histological study of the brain (cerebral cortex) revealed that the cerebral cortical layers of the aluminium treated groups appeared distorted and degenerated, in a dose-dependent manner. The study concluded that aluminium chloride has a neurotoxic effect on the cerebral cortex of adult Wistar rats which invariably may alter some cerebral functions.

*Keywords: Aluminium chloride; cerebral cortex; neurodegeneration; malondialdehyde.*

## 1. INTRODUCTION

Increasing concern has been raised to the effect that the human organism is constantly and inevitably exposed to aluminium, a ubiquitous metal which is known to be the third most abundant element in the Earth's crust, representing 8% of total components [1]. The report has shown that aluminium is a toxicant substance that is implicated in dialysis encephalopathy [2] osteomalacia [3], non-iron responsible anaemia [4], and also associated with many other diseases including Alzheimer's disease [5], Parkinson's disease [6] and amyotrophic lateral sclerosis [7].

Previous investigation has indicated that aluminium entry into the brain primarily occurs through the blood-brain barrier (BBB). Additionally, the mechanism(s) responsible for aluminium transport across the BBB is not fully understood, it has been reported from other studies that aluminium can penetrate into the brain as a complex with transferrin by a receptor-mediated endocytosis [8] and bound to citrate via a specific transporter, the system  $Xc^-$  (l-glutamate/l-cysteine exchanger) being the most recently accepted principles [9]. The apparently long half-life of aluminium in brain tissue has been advanced to explain its possible accumulation in the brain [10-11], which coupled with the long life of neurons may be responsible for the elevated levels of aluminium found in the brain of some patients suffering Parkinson's disease [6] and Alzheimer's disease [12].

Report from previous studies has shown increasing evidence which demonstrated that

oxidative stress is the primary and leading cause of pathogenesis in metabolic, inflammatory, partial ischemia and denatured cranial nerve disease [13]. It has been documented that the brain tissues are highly vulnerable and susceptible to oxidative damage, probably due to high oxygen consumption rate (20%), the availability of abundant polyunsaturated fatty acids in cell membranes, high iron (Fe) content coupled with low anti-oxidative enzyme activities [14]. Additionally, reactive oxygen species may also cause cellular damage, by oxidizing amino acid residues on proteins, resulting ultimately in protein carbonyls [15].

Findings from several studies have demonstrated that oxidative stress induced by aluminium leads to modification of the peroxidation of lipids and the activities of anti-oxidative enzymes. Julka and Gill [16]. However, reactive oxygen species can be beneficial, as they are used by the immune system as a way to attack and kill pathogens [17]. Short-term oxidative stress may also be important in the prevention of ageing by induction of a process named mitohormesis [18]. Chemically, oxidative stress is associated with increased production of oxidizing species or a significant decrease in the effectiveness of antioxidant defences, such as glutathione [19].

Production of reactive oxygen species is a particularly destructive aspect of oxidative stress. Such species include free radicals and peroxides. Most long-term effects of oxidative stress are caused by damage to DNA [20]. Oxidative stress is suspected to be important in neurodegenerative diseases including Lou Gehrig's disease (aka MND or ALS), Parkinson's

disease, Alzheimer's disease, Huntington's disease, Depression, Autism and Multiple sclerosis [21]. Aluminium chloride as one of the toxic metals has been known to be the major environmental pollutant across the world which has led to the discovery of diverse neurodegenerative diseases (ND) associated with metallic intoxication [22]. Aluminium has the capacity to be neurotoxic both in human and animals. It is present in many pharmaceutical drugs, food products and also used in the treatment of drinking water being involved in skeletal, haematological and neurological diseases. Aluminium is widely used in antacid drugs as well as in food additives and toothpaste [23]. Furthermore, other studies have revealed that there are possible adverse effects of aluminium on human health with no known physiological role for aluminium within the body. Aluminium neurotoxicity has been a matter of serious concern to scientists in view of several investigations conducted in relation to aluminium toxicity. Chronic exposure of animals to aluminium is associated with behavioural, neuropathological and neurochemical changes including altering behaviours, anxiety, depression, weakness etc. Aluminium toxicity has been implicated in many neurodegenerative disorders such as Parkinson's disease (PD), Alzheimer's disease (AL), Parkinsonism-Dementia, amyotrophic lateral sclerosis, dialysis encephalopathy etc [24]. A possible link between aluminium and Alzheimer's disease has been highlighted, and a variety of animals and human studies have implicated learning and memory deficit after aluminium exposure [25]. This study investigated some effects of aluminium chloride on the cerebral cortex of Wistar rats in view of the previously reported adverse effects of aluminium chloride.

## 2. MATERIALS AND METHODS

This study was conducted at the animal house of the Department of Human Anatomy, Ladoko Akintola University of Technology, Ogbomoso, Oyo state, Nigeria. Thirty-two healthy adult Wistar rats of both sexes weighing 110-240 g were used for this study. The experimental animals were housed in a standard plastic cages, fed with rat chow, and took water *ad libitum*. The experimental animals were weighed and randomly divided into four groups comprising eight rats in each group after acclimatization. The preliminary studies, animal acclimatization, actual animal experiment and evaluation of results, lasted for a period of three months.

However, the actual administration of aluminium chloride lasted for three weeks. The animals were housed in serene and conducive cross ventilated room in the Animal Holding of Department of Anatomy, Ladoko Akintola University of Technology, Ogbomoso, Nigeria and treated in accordance with 'Guide for the care and use of Laboratory Animal' prepared and compiled by the National Academy Of Science and published by the National Institute of Health[26].

**Group A:** Rats received distilled water and they served as control.

**Group B:** Rats in this group received 0.2 g/kg, of aluminium chloride (low dose) orally for 3 weeks.

**Group C:** Rats in this group received 0.4 g/kg of aluminium chloride (medium dose) orally for 3 weeks.

**Group D:** Rats in this group received 0.6 g/kg of aluminium chloride (high dose) orally for 3weeks. The Wistar rats were sacrificed by cervical dislocation on the 22<sup>nd</sup> day of the treatment and the brain of each rat was immediately excised and weighed using a sensitive analytical weighing balance before fixing in 10% buffered formalin for histological analysis. The cerebral cortexes of the right hemisphere were excised and homogenized for assessment MDA, SOD and SDH. The other halves of the brains were used for histological procedures using Haematoxylin and Eosin.

Cortical malondialdehyde (MDA) level was estimated in the respective homogenate samples obtained from each group by employing the procedure of Vashney and Kale (1990). Lipid peroxidation was carried out by measuring the Thiobarbituric Acid – Reactive (TBAR) products. The method was based on the formation of the pink coloured product when 2-thiobarbituric acid (TBA) reacts with MDA in an acidic medium for 30min to form thiobarbituric acid reactive substances (TBARS). The absorbance of the resultant pink product was measured spectrophotometrically at 534nm. The SOD activity was estimated using the method of Mishra and Fridovich (1972), The assay was based on the ability of SOD to scavenge superoxide anion radical (O<sub>2</sub><sup>-</sup>) which by shortening or reduction reaction chain decreases the overall rate of pyrogallol autoxidation. Succinic dehydrogenase activity was determined by the method of Nichlas et al. (1960).

The Statistical analysis of the results in this study was carried out and tested for significance using Student's t-test. Data were expressed as means  $\pm$ SEM and analysis was done using descriptive and inferential statistical methods with the graph prism 5 for window version 5.02 trial (1992-2009).

### 3. RESULTS

From Table 1, the weight analysis for brain shows an insignificant difference ( $P>0.05$ ) in weight, comparing control group to group B, also there was an insignificant difference ( $P>0.05$ ) in weight of brain when group C and D were compared with the control Group A.

Group D which received the highest dose has the highest brain weight compared with other aluminium-treated groups, after the Group A which is the control, followed by group B which received the low dose and group C which received the medium dose.

Which shows that the effects of aluminium are not dosed dependent on brain weight.

### 4. BIOCHEMICAL ANALYSIS

Table 2 reveal a rapid decrease in the activity of SOD in the aluminium-treated rats when compared with the control, it decreased significantly ( $P<0.05$ ) from  $78.34 \pm 33.0$  to  $33.07$

$\pm 1.37$  in group B,  $60.42 \pm 4.48$  in Group C and  $45.63 \pm 9.96$  in group D.

The level of MDA (malondialdehyde) increased significantly ( $P<0.05$ ) in the treated groups compared with the control. It increased from  $33.06 \pm 1.37$  in group A to  $39.74 \pm 2.06$  in group B,  $60.42 \pm 4.48$  in group C and  $51.42 \pm 9.65$  in group D. The SDH level decreases in all the aluminium-treated groups in relation with the control. There was a significant decrease ( $P<0.05$ ) in the level of SDH in group C and D of the aluminium-treated groups compared with the control, it decreased from  $2.91 \pm 0.24$  in group A to  $2.23 \pm 0.44$  in group B,  $1.37 \pm 0.15$  in group C and  $1.17 \pm 0.11$  in group D.

### 5. HISTOLOGICAL FINDINGS

**Group A (control):** The histological examinations show a normal cerebral cortex histological morphology, the cells are normal as it could be seen in the photomicrograph (plate A). The cells are well arranged with normal nucleus, pyramidal cells and organized molecular layers there is no sign of degenerations or distorted cells.

**Group B (low dose):** This group received 0.2mls of aluminium chloride. The histological examination shows a slightly distorted cell with loss of their process, mild generative changes occur in the cytoplasm and condensed nuclei are seen. Morphology (molecular layer) is similar to that of group A.

**Table 1. The mean  $\pm$  sem of brain weights of adult Wistar rats after administration of aluminium chloride for 21 days**

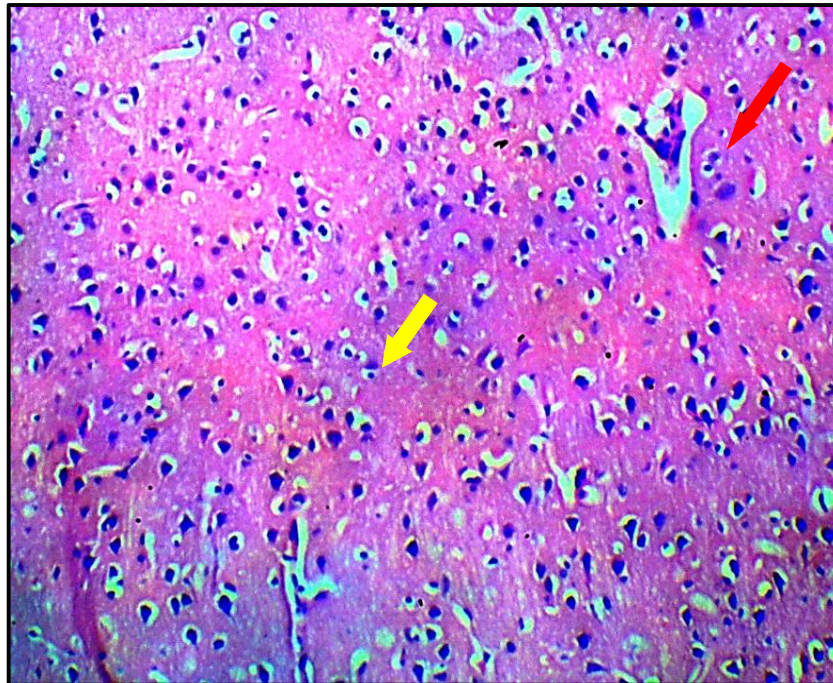
Groups	Mean $\pm$ SEM of brain weight	Relative brain weight %
Group A (Control)	$1.95 \pm 0.035$	1.03%
Group B Low Dose (0.2g/kg)	$1.55 \pm 0.068$	0.97%
Group C Medium Dose (0.4g/kg)	$1.48 \pm 0.091$	0.93%
Group D High Dose (0.6g/kg)	$1.55 \pm 0.096$	1.02%

**Table 2. Effect of aluminium chloride on the activities of superoxide dismutase (SOD), malondialdehyde (MDA) and succinate dehydrogenase (SDH) in the brain**

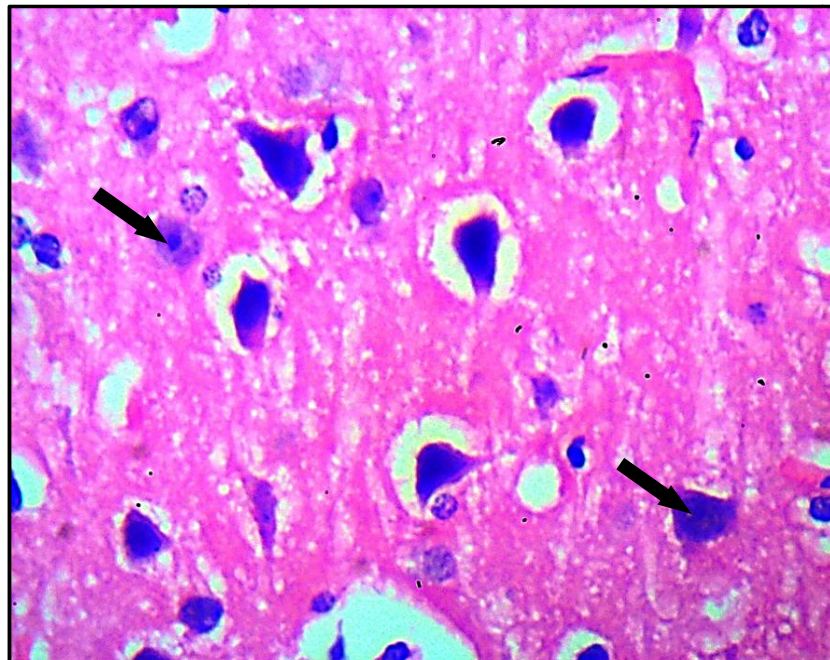
Parameter	Group A	Group B	Group C	Group D
	Mean $\pm$ SEM	Mean $\pm$ SEM	Mean $\pm$ SEM	Mean $\pm$ SEM
SOD ( $\eta$ mol/gtIssue)	$78.34 \pm 7.81$	$33.07 \pm 1.37^*$	$60.42 \pm 4.48^*$	$45.63 \pm 9.96^*$
MDA ( $\eta$ mol/gtIssue)	$33.06 \pm 1.37$	$39.74 \pm 2.06^*$	$60.42 \pm 4.48^*$	$51.42 \pm 9.65^*$
SDH ( $\mu$ mol/gtissue)	$2.91 \pm 0.24$	$2.23 \pm 0.44$	$1.37 \pm 0.15^*$	$1.17 \pm 0.11^*$

Data were represented as Mean  $\pm$  SEM ; \*  $P<0.5$  statistically different from the control; SEM; Standard Error of Mean; SOD: Superoxide dismutase; MDA: Malondialdehyde; SDH: Succinate Dehydrogenase

**Histological observation (Photomicrograph of the Histology)**



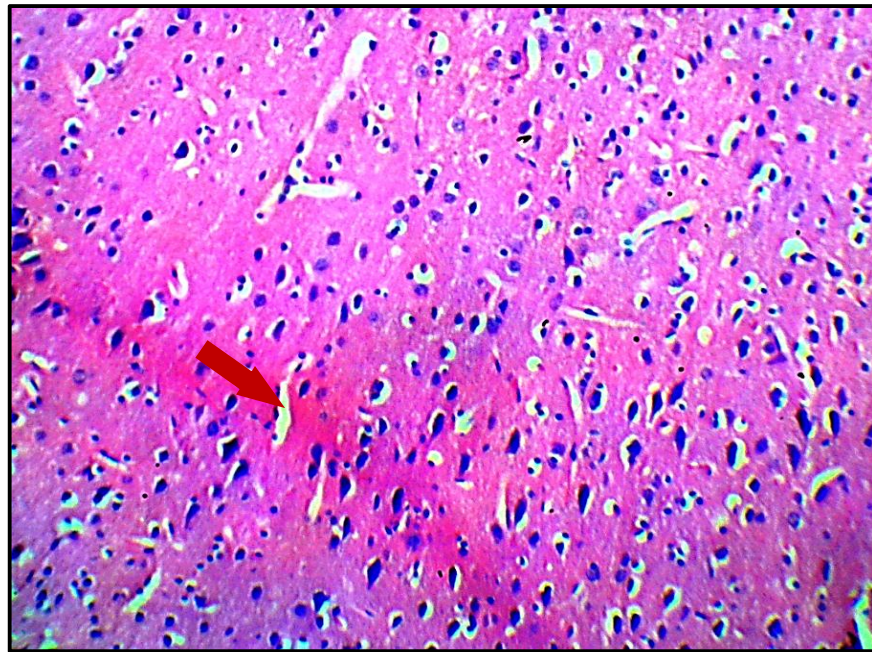
X 100



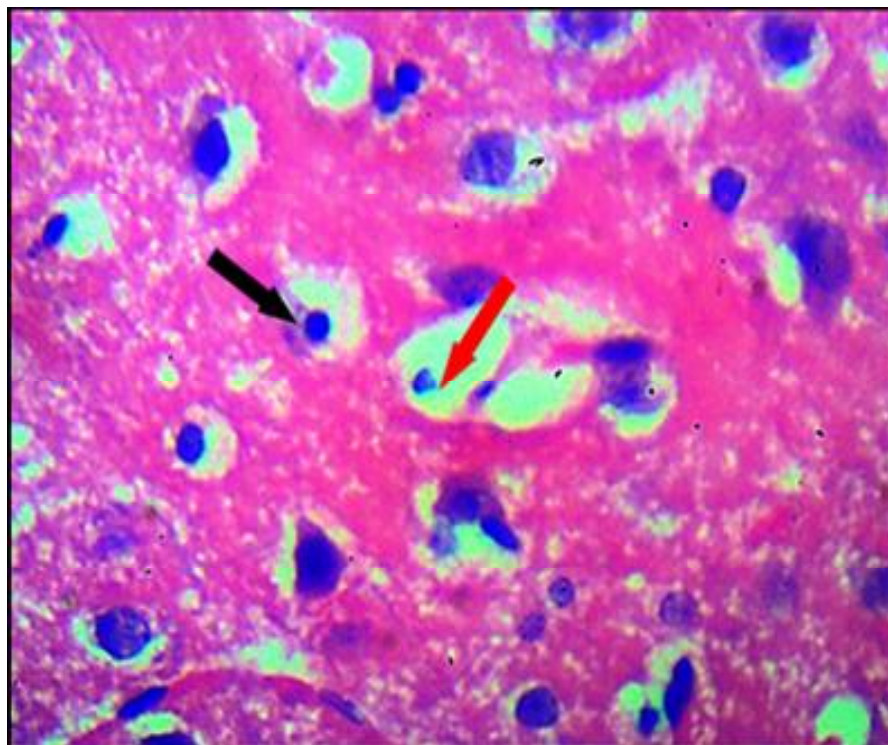
X 400

**Group A. Control group**

*Plate A: Photomicrograph control group showing a normal histological feature of the cerebral cortex, characterized by large pyramidal cell (black arrow), with long axons (white lines) that extends well from the delineated soma of the pyramidal neurons, normal molecular layers (yellow arrow) and external granular layer (red arrow) also appear normal. (H & E X100 X400)*



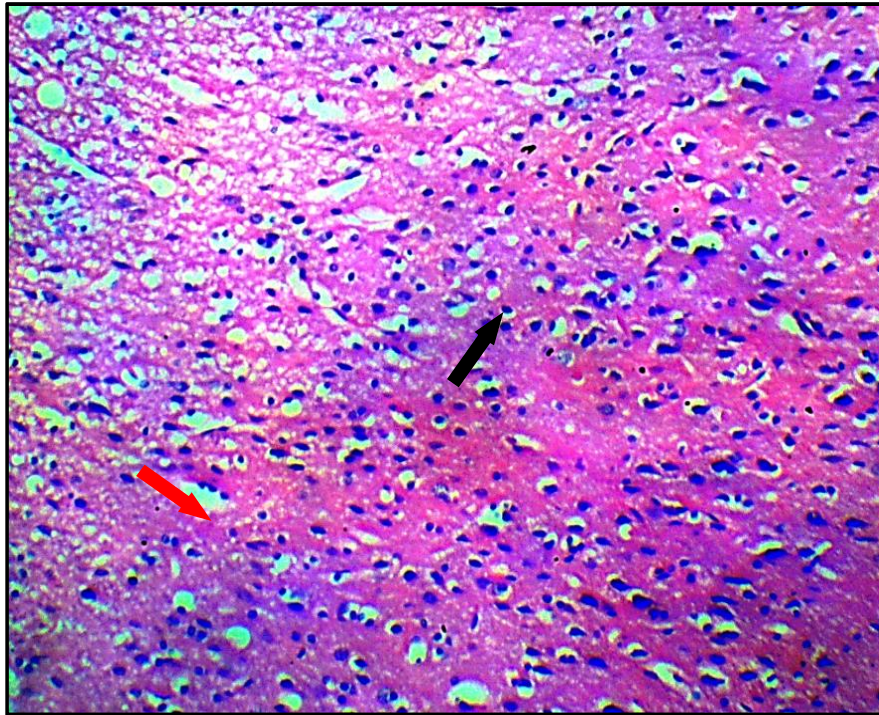
X 100



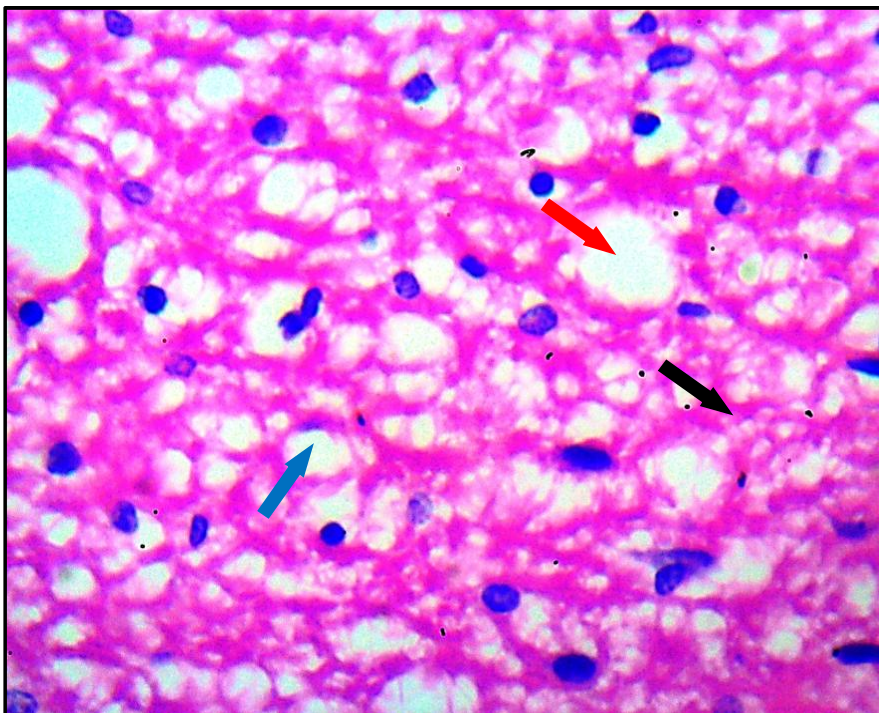
X 400

**Group B. Exposed to 0.2 mls of aluminum chloride**

*Plate B: Photomicrography of group B administered 0.2 mls/kg of Aluminium chloride, showing slightly mild generative changes in the pyramidal cell, which appear slightly distorted with loss of their process (black arrow), mild generative changes occur in the cytoplasm and condensed nuclei is seen (red arrow). Morphology (molecular layer) is similar to that of group A. (H & E X100 X400)*



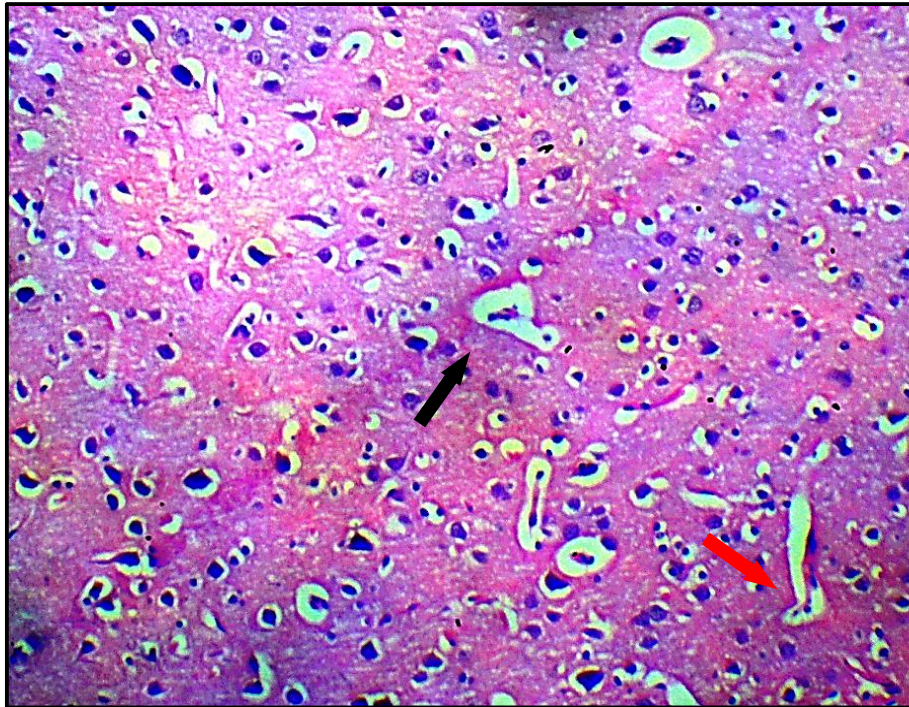
X 100



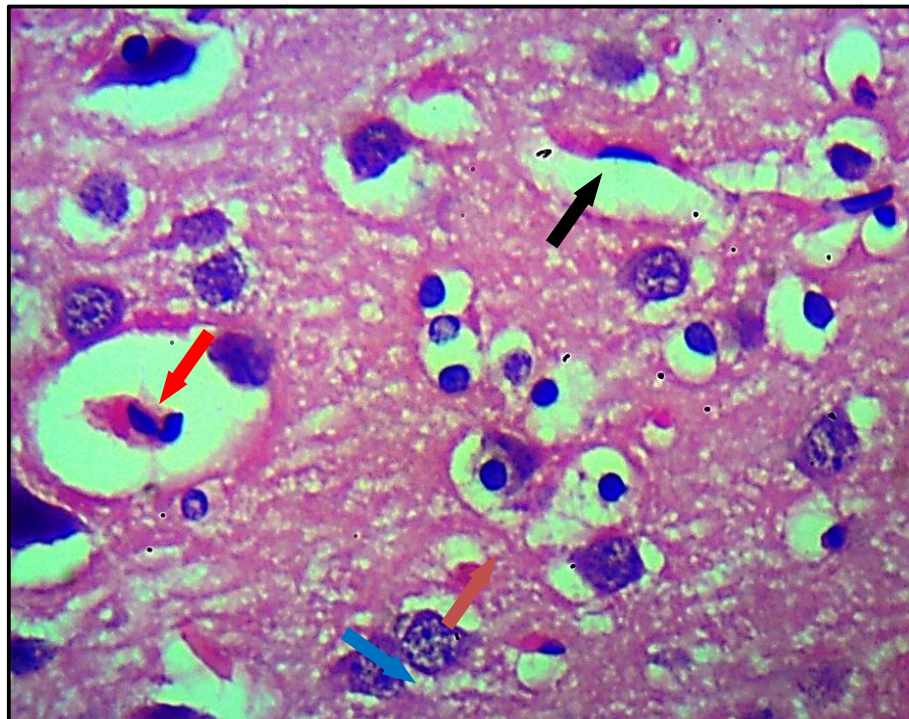
X 400

**Group C: Administered 0.4 mls of lead chloride**

*Plate C: Photomicrograph of group B, administered 0.4mls/kg of Aluminium chloride showing loss of pyramidal cells due to degeneration, leading to plenty of perineural spaces (red arrow), molecular layers appear unorganized with lots of spaces (black arrow) , cell distortion was very obvious (blue arrow). (H & E X100 X400)*



X 100



X 400

**Group D: Exposed to 0.6 mls of aluminum chloride**

*Plate D: photomicrograph of group D administered 0.6 mls/kg of aluminium chloride showing severe degeneration in fragmented cytoplasm, condensed nuclei within soma (black arrow), very large and numerous Perineural space can surrounding degenerating neurons (red arrow), neurofibril tangle (brown arrow), spaces within the pyramidal cells and granular layer (blue arrow). (H & E X 100 X 400)*



**Group C (medium dose):** This group received 0.4mls of aluminium chloride. The histological examination as it could be seen in the photomicrography shows loss of pyramidal cells due to degeneration, leading to plenty of perineural spaces, molecular layers appear unorganized with lots of spaces, cell distortion was very obvious, compare with plate A and plate B.

**Group D (high dose):** This group received 0.6mls of aluminium chloride. The histological examinations show a severe degeneration in fragmented cytoplasm, condensed nuclei within the soma, very large and numerous Perineural space can surrounding degenerating neurons, neurofibril tangle, spaces within the pyramidal cells and granular layer, axon and dendrite are scarcely appreciable around neurons.

## 6. DISCUSSION

Findings from previous studies have indicated that the cortex is region known to be particularly susceptible in Alzheimer's disease and performs an important role in learning and memory functions [25] Reports from Several studies have suggested a general decline in learning abilities which are mediated by aluminium toxicity [27]. Results from the present study demonstrated a significant increase ( $P < 0.05$ ) in lipid peroxidation following aluminium exposure in treated adult Wistar rats, measured in terms of TBARS levels in the rat brain. Similarly, other investigators have also reported a significant increase ( $P < 0.05$ ) in whole brain thiobarbituric acid reactive substances after treatment with aluminium salts. Additionally, it has been reported from previous investigations, that aluminium is a non-redox metal whose accumulation in the brain has been implicated in various neurodegenerative diseases [28,3]. Several hypotheses from various investigators have been written to explain the potentials ability of aluminium to promote biological oxidations [29]. Thus, it has been shown to facilitate iron-induced lipid peroxidation [30], non-iron-induced lipid peroxidation [31], non-iron-mediated oxidation of NADH [32] and non-iron-mediated formation of the hydroxyl radical [33]. Additionally, aluminium also appears to inhibit several antioxidant enzymes in different parts of the brain [34]. The significant variations and reductions in antioxidant enzyme activities in this study are adequately supported by findings from previous reports. Furthermore, The result

of variations in antioxidant status is consistent with similar behavioural patterns of a significant decrease in the enzyme activity of most antioxidant systems, and agree with previous studies [35,36,34,37] (Dua and Gill 2001; Abubakar *et al.* 2004a; Nehru and Anand 2005; Jyoti *et al.* 2007). Findings from previous studies on adult animals have shown that Aluminium-induced the production of ROS and caused oxidative damage in the brain [38]. Additionally, reactive oxygen species can also cause cellular damage, by oxidizing amino acid residues on proteins, forming protein carbonyls, Similarly, it has been reported that aluminium (Al) is a relatively low redox mineral, which has the potential to induce oxidative damage through multiple mechanisms. It has the tendency to bind negatively charged brain phospholipids, which possess polyunsaturated fatty acids and are readily attacked by reactive oxygen species (ROS) such as  $O_2^-$ ,  $H_2O_2$ ,  $OH$ , and  $OH$ [38]. Furthermore, it has been suggested that oxidative stress caused by high Al content is greater than the protection provided by the anti-oxidizing system; subsequently leading to the high possibility of oxidative damage to brain tissue [39]. It has been reported that Al concentration in the brain tissue increased with increasing Al intake, but not in a dose-dependent manner and consequently oxidative damage occurred in specific brain areas of adult rats [40]. Aluminium has been shown by studies to be bound by the  $Fe^{3+}$  carrying protein transferrin thus reducing invariably the binding of  $Fe^{2+}$ . Moreover, it has been observed that the increase in free intracellular  $Fe^{2+}$  causes the peroxidation of membrane lipids and thus causes membrane damage [41]. Similarly, Aluminium (Al) is widely known to be a neurotoxin that inhibits more than 200 biologically important functions in organisms [41].

This study as indicated above investigated some effects of aluminium chloride on the cerebral cortex, the result showed that rats treated with aluminium chloride resulted in an insignificant decrease in mean brain weights. However, in some studies, it was reported that aluminium chloride increased the brain weight of Wistar rats after the animals were exposed to aluminium chloride for 30 days [49]. Microscopic examination of the cerebral cortex In the group B (induced 0.2 MLS  $AlCl_3$ ) only slight and mild distortions were observed in the architecture of the brain, the architecture of the brain in group C and D animals that were treated on higher dose (0.4 ml and 0.6mls respectively), a more

prominent and significant damage was observed in the brain, it was also observed that animals in various groups demonstrated a dose-dependent damage in the cerebral cortex of aluminium-treated rats as observed in this study. The histological alterations and distortions in the histo-architecture of the cortical layers in the treated rats and these findings are consistent with and corroborate the reports of previous studies [42,43,44]. The alteration in the histological layers may have been the reason behind the reduction in weight of the brain across the aluminium treated group, which correlate with [45]. The finding from this study supports the hypothesis that aluminium has potential role in neurodegenerations [46]. The results of biochemical parameters investigated showed an elevated level of MDA activity in the aluminium treated groups (group B, C and D) when compared with the control group (group A), lipid peroxidation generates MDA which is major indicator for oxidative damage initiated by reactive oxygen species (ROS) and causes impairment in cell membrane function [47]. The increase in lipid peroxidation observed in this study may be attributed to the direct effect of an increase in the generation of reactive oxygen species (ROS) resulting from aluminium chloride administration similar observation here earlier been reported in studies involving the brain [48]. Several studies have implicated oxidative stress in the pathogenesis of a number of disorders and the severity of damage is generally associated with an increase or decrease of one or more free radical scavenging enzymes [49].

The increased lipid peroxidation in aluminium-treated rats in this study, may be due to an inhibition of SOD activity in the brain. The result is a substantial increase in the rate of phospholipid peroxidation in brain cells, leading to membrane damage and neuron death. The activity of SOD decreased significantly in aluminium-treated groups when compared with the control. The significant decrease in the activity of this enzyme might be the result of enzyme inactivation by reactive oxygen species resulting in a significantly decreased activity, similarly, a decreased activity of this enzyme is also an indication of the increased level of lipid peroxidation caused by the effect of aluminium chloride. The activities as SDH also decreased across the aluminium-treated Group when compared with the control group (group A) which may have been due to the toxicity of aluminium chloride leading to changes in metabolism of

non-essential animal acid, which could lead to decrease function of mitochondrial cell respiration and energy generation which correlate with the findings of research carried out by previous investigator [50]. This project has presented consisted of information from all result including the histological and biochemical analysis confirming the damaging effect of Aluminium on the cerebral cortex.

## 7. CONCLUSION

The study concluded that exposure to aluminium chloride resulted in oxidative cerebral cortical damage in wistar rats as observed in aluminium-treated rats which invariably may result in a compromise of cerebral functions.

## CONSENT

It is not applicable.

## ETHICAL APPROVAL

All authors hereby declare that the principles of laboratory animal care [NIH publication No. 85-23 revised 1985] were followed as well as specific national laws where applicable. All experiments have been examined and approved by the relevant ethics committee. All authors hereby declare that all experiments have been examined and approved by the appropriate ethics committee and therefore have been performed in accordance with the ethical standards laid down in the 1964 Declaration of Helsinki.

## COMPETING INTERESTS

Authors have declared that no competing interests exist.

## REFERENCES

1. Martin RB. Chemistry of aluminum in the central nervous system, in *Mineral and Metal Neurotoxicology* (Yasui M, Strong M, Ota K, Verity MA, eds). 1997;80:75–80. CRC Press, Boca Raton, Florida.
2. Alfrey A, Le Gendre G, Kaehny W. The dialysis encephalopathy syndrome: Possible Aluminum Intoxication. *N. Engl. J. Med.* 1976;294:184–188.

3. Parkinson IS, Feest TG, Kerr DNS, Ward MK, Fawcett P. Fracturing dialysis osteodystrophy and dialysis encephalopathy: An Epidemiological Survey. *Lancet*. 1979;313:406–409.
4. Elliott HL, Dryburgh F, Fell GS, Sabet S, Maccougall AI. Aluminum toxicity during regular haemodialysis. *Br. Med. J.* 1978;1: 1101– 1103.
5. Gupta VB, Anitha S, Hegde ML, Zecca L, Garruto RM, Ravid R, Shankar SK, Stein R, Shanmugavelu P, Jagannatha Rao KS. Aluminium in Alzheimer's disease: Are we still at a crossroad? *Cell. Mol. Life Sci* 2005;62:143–158.
6. Yasui M, Kihira T, Ota K. Calcium, magnesium and aluminum concentrations in Parkinson's disease. *Neurotoxicology*. 1992;13:593–600.
7. Kurland LT. Amylotrophic lateral sclerosis and Parkinson's disease complex on Guam linked to an environmental neurotoxin. *Trends Neurosci*. 1988;5, 1151–1158.
8. Roskams AJ, Connor JR. Aluminum access to the brain: A role for transferrin and its receptor. *Proc. Natl Acad. Sci. USA*. 1990;87:9024–9027.
9. Nagasawa K, Ito S, Kakuda T, Nagai K, Tamai I, Tsuji A, Fujimoto S. Transport mechanism for aluminium citrate at the blood-brain barrier: Kinetic evidence implies involvement of system Xc<sup>-</sup> in immortalized rat brain endothelial cells. *Toxicol. Lett*. 2005;155:289–296.
10. Yokel RA, Rhineheimer SS, Sharma P, Elmore D, McNamara PJ. Entry, half-life, and desferrioxamine-accelerated clearance of brain aluminum after a single <sup>26</sup>Al exposure. *Toxicol. Sci*. 2001;64:77– 82.
11. Sánchez-Iglesias S, Soto-Otero R, Iglesias-González J, Barciela-Alonso MC, Bermejo-Barrera P, Méndez-Álvarez E. Analysis of brain regional distribution of aluminium in rats via oral and intraperitoneal administration. *J. Trace Elem. Med. Biol*. 2007b;21:31–34.
12. Perl DP, Brody AR. Alzheimer's disease: X-ray spectrometric evidence of aluminum accumulation in neurofibrillary tangle-bearing neurons. *Science*. 1980; 208:297–299.
13. Love S, Jenner P. Oxidative stress in neurological disease. *Brain Pathol*. 1999;9:55–56.
14. Youdim MB. Iron in the brain: Implications for Parkinson's and Alzheimer's diseases. *Mt Sinai J Med*. 1988;55(1):97– 101.
15. Chevion M, Berenshtein E, Stadtman ER. Human studies related to protein oxidation: Protein carbonyl content as a marker of damage. *Free Radic Res*. 2000;33:99– 108.
16. Julka D, Gill KD. Effect of aluminum on regional brain antioxidant defense status in Wistar rats. *Res. Exp. Med*. 1996;196: 187–194.
17. Segal AW. How neutrophils kill microbes. *Annu Rev Immunol*. 2005;23(5):197–22.
18. Gems D, Partridge L. Stress-response hormesis and aging: That which does not kill us makes us stronger (PDF). *Cell Metab*. 2008;7(3):200–3.
19. Schafer FQ, Buettner GR. Redox environment of the cell as viewed through the redox state of the glutathione disulfide/glutathione couple. *Free Radic. Biol. Med*. 2001;30(11):1191– 212.
20. Evans MD, Cooke MS. Factors contributing to the outcome of oxidative damage to nucleic acids. *Bio Essays*. 2004;26(5):533–42.
21. Patel VP, Chu CT. Nuclear transport, oxidative stress and neurodegeneration. *Int J Clin Exp Pathol*. 2011;4(3):215–29.
22. Kloppel H, Fliedner A, Kordel W. Behaviour and endotoxicology of aluminium in soil and water. Review of the Scientific Literature. *Chemosphere*. 1997; 35:353-363.
23. Abbasali KM, Zhila T, Farshad N. Developmental toxicity of aluminium from high doses of AlCl<sub>3</sub> in mice. *The Journal of Applied Research*. 2005;5:575- 579.
24. Buraimoh AA, Ojo SA, Hambolu JO, Adebisi SS. Effects of oral administration of aluminium chloride on the Histology of the hippocampus of Wistar rats. *Current Research Journal of Biological Sciences*. 2011;3(5):509-515.
25. Niu Q, Yang Y, Zhang Q, Niu P, He S, Di Gioacchino M, Boscolo P. The relationship between Bcl-2 gene expression and learning & memory impairment in chronic Aluminium-exposed rats. *Journal of Biological Chemistry*. 2007;12(3):163- 169.

26. National Research Council. *Neem: A tree for solving global problems*. National Academy Press, Washington, DC; 1992.
27. Kankofer M. Superoxide dismutase and glutathione peroxidase activities in bovine placenta: Spectrophotometric and electrophoretic analysis. *Rev. Med. Vet* 2002;153:121-124.
28. Yokel RA. The toxicology of aluminium in the brain: a review. *Neurotoxicology*. 2000; 21:813–828.
29. Zatta P, Lucchini R, Van Rensburg SJ, Taylor A. The role of metals in neurodegenerative processes: Aluminum, manganese and zinc. *Brain Res. Bull* 2003;62:15–28.
30. Gutteridge JMC, Quinlan GJ, Clark I, Halliwell B. Aluminium salts accelerate peroxidation of membrane lipids stimulated by iron salts. *Biochem. Biophys. Acta*. 1985;835:441– 447.
31. Verstraeten SV, Oteiza PI. Effects of Al<sup>3+</sup> and related metals on membrane phase state and hydration: correlation with lipid oxidation. *Arch. Biochem. Biophys.* 2000; 375:340–346.
32. Kong S, Liochev S, Fridovich I. Aluminum (III) facilitates the oxidation of NADH by the superoxide anion. *Free Radic. Biol. Med.* 1992;13:79–81.
33. Méndez-Álvarez E, Soto-Otero R, Hermida-Ameijeiras A, López-Real AM, Labandeira-García JL. Effects of aluminum and zinc on the oxidative stress caused by 6-hydroxydopamine autoxidation: relevance for the pathogenesis of Parkinson's disease. *Biochim. Biophys. Acta*. 2002;1586:155–168.
34. Nehru B, Anand P. Oxidative damage following chronic aluminium exposure in adult and pup rat brains. *J. Trace Elem. Med. Biol.* 2005;19:203–208.
35. Dua R, Gill KD. Aluminium phosphide exposure: Implications on rat brain lipid peroxidation and antioxidant defence system. *Pharmacol. Toxicol.* 2001;89: 315–319.
36. Abubakar MG, Taylor A, Ferns GA. The effects of aluminium and selenium supplementation on brain and liver antioxidant status in the rat. *Afr. J. Biotech.* 2004;3:88–93.
37. Jyoti A, Sethi P, Sharma D. *Bacopa monniera* prevents from aluminium neurotoxicity in the cerebral cortex of rat brain. *J. Ethnopharmacol.* 2007;111:56–62.
38. Verstraeten SV, Nogueira LV, Schreier S, Oteiza PI. Effect of trivalent metal ions on phase separation and membrane lipid packing: Role in lipid peroxidation. *Arch Biochem Biophys.* 1997;338(1):121–127. DOI: 10.1006/abbi.1996.9810
39. Chia-Yi Y, Yih-Jing L, Guoo-Syng WH. Aluminum overload increases oxidative stress in four functional brain areas of neonatal brain. *J Biomed Sci.* 2012;19(1): 51.
40. Esparza JL, Gomez M, Rosa Nogue M, Paternain JL, Mallol J, Domingo JL. Melatonin reduces oxidative stress and increases gene expression in the cerebral cortex and cerebellum of aluminum-exposed rats. *J Pineal Res.* 2005;39(2):129–136. DOI: 10.1111/j.1600-079X.2005.00
41. Imene B, Omar K, Nouria H, Hadi AB, Kaddour T, Mansoria B, Abdelkader A, Mehmet O. Aluminium-induced behavioral changes and oxidative stress in developing rat brain and the possible ameliorating role of Omega-6/Omega-3 ratio. *J Bio Sci.* 2017;17(3):106-117.
42. Abdel Moneim AE. Evaluating the potential role of pomegranate peel in aluminum-induced oxidative stress and histopathological alterations in brain of female rats. *Biol. Trace Elem. Res.* 2012;150:328–336.
43. Ebtessam M, Manal FE, Ahmed EA. The protective properties of melatonin against aluminium-induced neuronal injury *Int J Exp Pathol.* 2015;96(3):196–202.
44. Bhadauria M. Combined treatment of HEDTA and propolis prevents aluminum induced toxicity in rats. *Food Chem. Toxicol.* 2012;50:2487–2495.
45. Lipman JJ, Colowick SP, Lawrence PL, Abumard NN. Aluminium induced encephalopathy in the rat, *Life Sci.* 1988;42:463-875.
46. Gupta VB, Anitha G, Hegda ML, Zecca L, Garruto RM, Ravid R, Shankar SK, Stein R, Hanmugavelu P, Jagannatha Rao KS. Aluminium in Alzheimer's disease: Are we still at a crossroad? *Cellular Molecular Life Science.* 2005;62:143-158.
47. Halliwell B, Gutteridge JMC. *Free radicals in biology and medicine*, Oxford University Press, Oxford, UK, 2nd edition; 1989.
48. Buraimoh AA, Ojo SA, Hambolu JO, Adebisi SS. Effects of oral administration

- of aluminium chloride on the Histology of the Hippocampus of Wistar Rats. Current Research Journal of Biological Sciences. 2011;3(5):509-515. [ISSN: 2041-0778]
49. Savory J MM, Herman and Ghribi O. Intracellular mechanisms underlying aluminum-induced apoptosis in rabbit brain. J. Inorg. Biochem. 2003;97:151-154.
50. Panda SK, Yamamoto Y, Kondo H, Matsumoto H. Mitochondrial alterations related to programmed cell death in tobacco cells under aluminium stress. C. R. Biol. 2008;331:597-610.

© 2019 Ajibade et al.; This is an Open Access article distributed under the terms of the Creative Commons Attribution License (<http://creativecommons.org/licenses/by/4.0>), which permits unrestricted use, distribution, and reproduction in any medium, provided the original work is properly cited.

*Peer-review history:*  
*The peer review history for this paper can be accessed here:*  
<http://www.sdiarticle3.com/review-history/49605>