

## Effect of Sweet Potato (*Ipomoea batatas*) Tuber on Sperm Profile and Testicular Integrity of Male Albino Rats

P. B. Ekpo<sup>1</sup>, U. U. Uno<sup>1,2\*</sup>, H. O. Ogbe<sup>2</sup> and U. B. Ekaluo<sup>1</sup>

<sup>1</sup>Department of Genetics and Biotechnology, University of Calabar, Calabar, Nigeria.

<sup>2</sup>Department of Biology, Cross River State College of Education, Akamkpa, Nigeria.

### Authors' contributions

This work was carried out in collaboration between all authors. Author UUU designed the study, performed the statistical analysis, wrote the protocol and wrote the first draft of the manuscript. Authors PBE and HOO managed the analyses of the study. Author UBE managed the literature searches. All authors read and approved the final manuscript.

### Article Information

DOI: 10.9734/ACRI/2017/35820

#### Editor(s):

(1) Ayona Jayadev, Department of Environmental Sciences, All Saints' College (Government Aided College Affiliated to University of Kerala), India.

#### Reviewers:

(1) Alphonse Juma Odondo, Maseno University, Kenya.

(2) Hanan E.-S. Ali, Egyptian Petroleum Research Institute, Egypt.

Complete Peer review History: <http://www.sciedomains.org/review-history/20620>

Original Research Article

Received 30<sup>th</sup> July 2017  
Accepted 19<sup>th</sup> August 2017  
Published 23<sup>rd</sup> August 2017

### ABSTRACT

**Aim:** Globally, plant parts have been used for several purposes such as medicinal additives and food supplement. This is not unconnected to the fact that one or more parts of almost all plants contain active ingredients with medicinal and therapeutic properties. Hence, the study was conducted to determine the effect of sweet potato (*Ipomoea batatas*) tuber extract on the weight of testes and epididymes, epididymal sperm count, motility, viability, semen pH, sperm head abnormality and histology of testes in albino rat models.

**Place and Duration of the Study:** This study was carried out in the Animal house of the Department of Genetics and Biotechnology, University of Calabar, Calabar and lasted for 65 days.

**Methodology:** Twenty four male rats were randomly divided into four groups of six rats each using a completely randomized design. Group A served as control and received only water and pellet feed while group B, C and D received 200 mg/kg, 400 mg/kg and 600 mg/kg body weight of the aqueous extract of *Ipomoea batatas* tuber, respectively.

**Results:** Results obtained revealed that the tuber extract did not significantly affect the weight of

\*Corresponding author: Email: ukamuno@yahoo.com;

epididymes, sperm motility, sperm viability, sperm count, sperm head abnormalities and testicular integrity in the extract – treated animals when compared to the control group. No significant differences were also observed in semen pH and weight of testes (computed P value for weight of testes, weight of epididymes, sperm count, sperm motility, viability, semen pH and sperm head abnormality were 2.08, 1.89, 2.97, 2.63, 1.54, 2.30 and 1.08, respectively while the critical P value = 3.072 at 5% level of significance).

**Conclusion:** The findings of the study suggest that aqueous extract of *I. batatas* tuber does not have toxic effect on the sperm profile and testicular integrity of male albino rats.

**Keywords:** *Ipomoea batatas*; sperm quality; sperm count; sperm head abnormality; testicular integrity.

## 1. INTRODUCTION

The plant *Ipomoea batatas* commonly called sweet potatoes is a member of the convolvulaceae family with approximately 500 - 600 species making up the largest number of species within the convolvulaceae family. The family is dominated by climbing or twinning woody or herbaceous plants that usually have heart-shaped leaves and funnel-shaped flowers [1,2].

*Ipomoea batatas* is a tuberous-rooted perennial plant mainly grown annually. The roots are adventitious, mostly located within the top 25 cm of the soil. Some of the roots produce elongated starchy tubers. Tuber flesh colour can be white, yellow, orange and purple while skin colour can be red, purple, brown or white. The stems are creeping slender vines, up to 4 m long. The leaves are green or purplish, cordate, palmately veined, borne on long petioles [3,4]. Sweet potato leaves are used as vegetables for cooking; the tuber is also fried and eaten as food. Sweet potatoes can be used fresh, dried or ensiled. Like cereal grains, sweet potato root are rich in highly digestible starch and sugar and as such used a vital component of feed for ruminant [5].

*Ipomoea batatas* leaves extract have alterative, astringent, bactericide, aphrodisiac, laxative and tonic properties [6]. More so, a variety of white sweet potato is eaten raw to treat hypertension, anaemia and diabetes [7] while the root of *Ipomoea* species is used in the treatment of constipation [8]. Sweet potatoes and its derivatives are powerful antioxidant and may be potent in boosting the immune system and treating fever, asthma, bug bites, burns, catarrh, ciguatera, convalescence, diarrhoea, nausea, stomach distress, tumors and whitlows [1,3].

The leaves are also used in the treatment of diabetes, hookworm, hemorrhagic fever and

abscesses [9]. According to Udoh et al. [10], *Ipomoea batatas* leaves contain secondary metabolites which possess several actions including antioxidant, antimutagenic, anti-inflammatory, anti-carcinogenic and antifertility properties.

## 2. MATERIALS AND METHODS

### 2.1 Collection and Preparation of Plant Material

Tubers of sweet potato were bought from Watt market, Calabar, Cross River State of Nigeria and authenticated at the Department of Botany, University of Calabar, Calabar. The tubers were peeled, washed thoroughly and sliced into tiny pieces, sun-dried for 72 hours and pulverized using an electric blender.

A weighed quantity (100 g) of the powdered tuber sample was soaked in 500 ml of cold distilled water and allowed to stand for 48 h. The aqueous extract was obtained after filtering the suspension and stored in a refrigerator until used.

### 2.2 Experimental Animals

Twenty four healthy and sexually mature male albino rats of 12 weeks old were used in this study. The rats were obtained from the Experimental Animal Unit of Department of Genetics and Biotechnology, University of Calabar, Calabar. The rats were housed in conventional wire mesh cages under standard laboratory conditions. They were allowed free access to water and pellet feed throughout the period of the experiment. Generally, the study was conducted in accordance with the recommendation from the declarations of Helsinki on guiding principles in care and use of animals.

### 2.3 Experimental Design and Procedure

The twenty four male rats were randomly divided into four groups of six rats each using a completely randomized design. The animals were acclimatized for one week before the commencement of the study. Group A served as control and received only water and pellet feed while group B, C and D received 200 mg/kg, 400 mg/kg and 600 mg/kg body weight of the aqueous extract of *Ipomoea batatas* tuber, respectively. The rats were sacrificed under chloroform anaesthesia 24 h after the last treatment. The epididymes and testes were dissected out and weighed using Scout Pro SPU 601 electronic weighing balance. The epididymes were processed for epididymal sperm motility, viability, count and sperm head abnormality, semen pH and sperm motility: Immediately after dissection, a puncture was made in the epididymis with a sterile pin.

The semen smeared on the pin was rubbed on a pH paper of range 4.0-10.0. The colour change corresponds to the pH and was read from the paper. Two drops of sperm suspension was put on a microscope slide and cover slip was placed. The number of progressively motile cells was divided by the total number of spermatozoa counted under x40 lenses and expressed as a percentage [11].

### 2.4 Sperm Viability

The sperm viability test was determined using "Eosin-Nigrosin one-step staining technique" [11]. A portion of the sperm suspension was mixed with equal volume of Eosin-Nigrosin stain and four (4) air-dried smears were prepared on glass slides for each sample. The slides were examined for percentage viability. Normal live sperm cells excluded the stain and appeared whitish, whereas dead sperm cells took up stain and appeared pinkish. Percentage viability was calculated based on the number of live sperm cells out of the total number of sperm cells observed.

### 2.5 Sperm Count

The epididymal sperm samples were obtained by macerating known weights of cauda epididymes in physiological saline in the ratio of 1:10 weight by volume. After vigorous pipetting to release the sperm cells. The suspension was filtered using an 80 µm stainless mesh. Epididymal sperm

count was obtained by cytometry using the improved Neubauer cytometer and was expressed as million/mL of suspension [12].

### 2.6 Sperm Head Abnormality Test

A portion of the sperm suspension was mixed with 1% eosin Y solution (10:1) for 30 min and air-dried smears were prepared on glass slides for the sperm head abnormality test. The slides were examined for percentage sperm head abnormalities in every 200 spermatozoa observed on each slide and five air-dried smears were prepared on glass slides for each sample. The percentage of sperm head abnormality was calculated according to Ekaluo et al. [13].

### 2.7 Histology of Testes

The testes were fixed in 10% formol saline. The fixed tissues were transferred to a graded series of ethanol and then cleared in xylene. Once cleared, the tissues were infiltrated in molten paraffin wax in the oven at 58°C. Serial section of 5 µm thickness were obtained from the solid block of tissues, cleared, fixed in clean slide, stained with haematoxylin and eosin stains and examined with the light microscope.

### 2.8 Statistical Analysis

Data from weight of testes and epididymes, epididymal semen pH, motility, viability, count and sperm head abnormality were subjected to the Analyses of Variance (ANOVA) test while differences in means were separated using Least Significant Difference (LSD) test.

## 3. RESULTS AND DISCUSSION

### 3.1 Weight of Testes and Epididymes

There was no significant difference in the weights of the testes and epididymes of rats treated with the extract when compared to the control (computed P value for weight of testes and epididymes were 2.08 and 1.89 while the critical P value = 3.072 at 5% level of significance). The weight of the testes were 1.24, 1.26, 1.00 and 1.08 g while the epididymes weighed 0.58, 0.52, 0.44 and 0.54 g for the control, groups B, C and D, respectively as shown in Table 1.

### 3.2 Semen pH and Sperm Count

Results presented in Table 1 showed that there was no significant effect of the treatment on the semen pH and the sperm count when compared to the control. The control group had mean sperm count of  $13.10 \times 10^5 \text{ mL}^{-1}$  while group B, C and D had 15.40, 12.30 and  $11.80 \times 10^5 \text{ mL}^{-1}$ , respectively (computed P value for the semen pH and sperm count were 2.30 and 2.97, respectively while the critical P value = 3.072 at 5% level of significance).

### 3.3 Sperm Motility and Viability

The motility of the sperm cells did not differ significantly in groups of rats treated with the extract of *Ipomoea batatas* tuber when compared with the control as presented in Table 1. The control had 70.20% of motile cells while groups B, C and D had 66.20, 63.80 and 62.20%, respectively. There was also no significant difference in the percentage of viable sperm cells in the extract treated animals (79.40, 78.20, and 75.40%, respectively for groups B, C and D) when compared to the control being 78.60% (computed P value for sperm motility and viability were 2.63 and 1.54, respectively while critical P value = 3.072 at 5% level of significance).

### 3.4 Sperm Head Abnormality

Result obtained on the effect of the extract of sweet potato tuber is presented in Table 1. Animals treated with the extract had no significant difference in the percentage of sperm head abnormality (2.40, 2.80 and 3.00% for Group D, C and B, respectively) when compared to the control (2.20%) with the computed P value being 1.08 as against the critical value (3.072).

### 3.5 Histology of Testes

Histological examination of the testes in plate 1 revealed that the tuber extract did not alter the testicular integrity of the animals when compared to the control group. The testicular section of the control and different treatment groups indicated prominent seminiferous tubules of various sizes with intact basement membranes containing spermatogonia at various stages of maturation. There was absence of necrosis and degeneration of the cells.

## 4. DISCUSSION

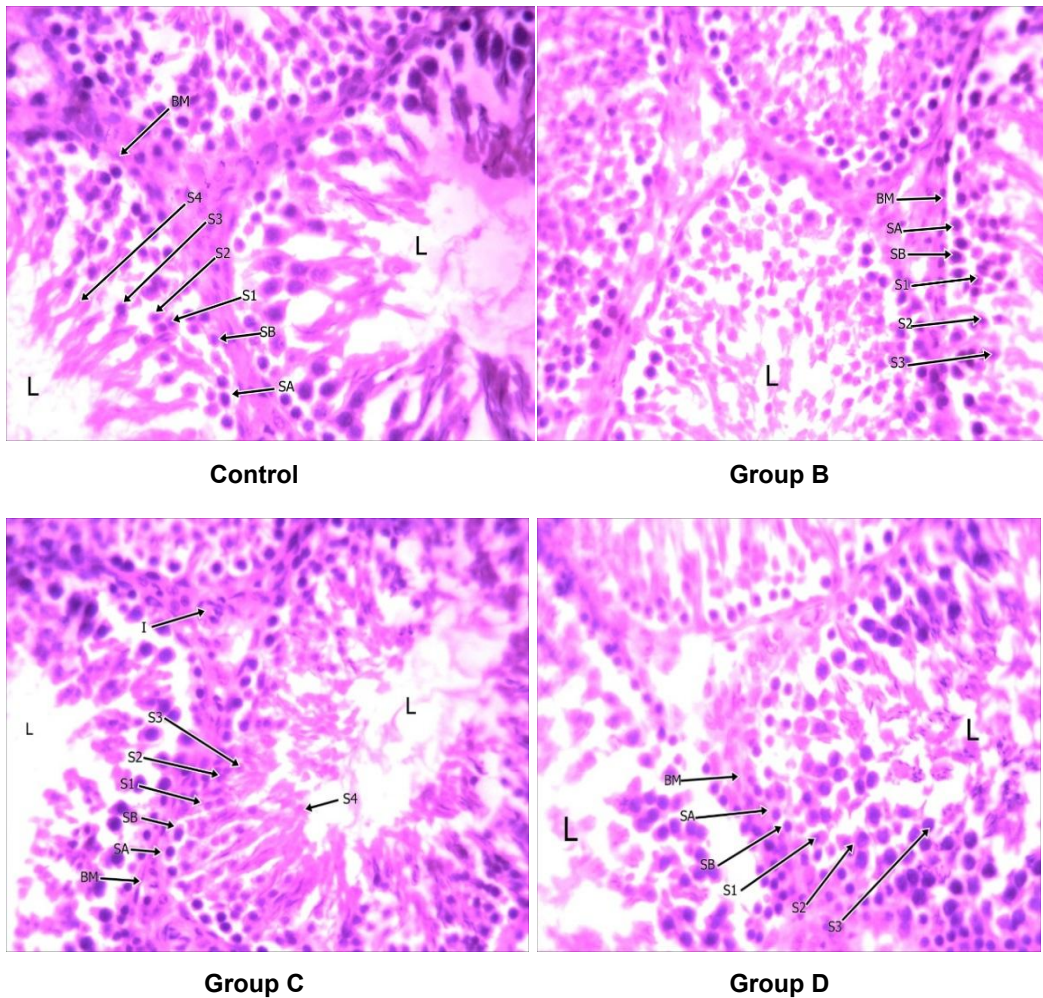
Results revealed that *I. batatas* tuber extract did not significantly ( $P=0.05$ ) affect the sperm profile of the treated rats which agrees with the findings of Adienbo [14]. This suggests that the phytonutrients and phytochemicals present in the tuber did not negatively alter spermatogenic processes in the treated animals. This assertion is supported by Ikpeme et al. [15] who opined that a disruption in spermatogenesis positively correlates with disruption in fertility indices such as sperm profile.

It was also observed from histological examination that the testicular integrity of the treated rats was not altered as a result of the treatment corroborating the results obtained on sperm profile. Testicular integrity has been shown to influence production of sex hormones binding globulin and sex hormones metabolic pathways and clearance rates [16,17]. More so, the physiological status of the testicular glands might also influence spermatogenesis and fertility in male rats [18,19,20]. Udoh et al. [10] had reported that the leaf extract of the plant had toxic effect on the testes causing hypertrophy and hyperplasia. Results obtained in the present study therefore allows for the suggestion that the

**Table 1. Effect of sweet potato (*Ipomoea batatas*) tuber extract on male rat**

Parameters	Group A control	Group B 200 mg/kg	Group C 400 mg/kg	Group D 600 mg/kg
Weight of testes (g)	1.24 <sup>a</sup> ± 0.07	1.26 <sup>a</sup> ± 0.08	1.00 <sup>a</sup> ± 0.14	1.08 <sup>a</sup> ± 0.10
Weight of epididymis (g)	0.58 <sup>a</sup> ± 0.07	0.52 <sup>a</sup> ± 0.04	0.44 <sup>a</sup> ± 0.02	0.54 <sup>a</sup> ± 0.02
Sperm count ( $\times 10^5 \text{ mL}^{-1}$ )	13.10 <sup>a</sup> ± 0.73	12.40 <sup>a</sup> ± 1.02	12.30 <sup>a</sup> ± 1.02	11.80 <sup>a</sup> ± 1.03
Sperm motility (%)	70.20 <sup>a</sup> ± 4.36	66.20 <sup>a</sup> ± 1.98	63.80 <sup>a</sup> ± 1.43	62.20 <sup>a</sup> ± 0.10
Sperm viability (%)	78.60 <sup>a</sup> ± 3.23	79.40 <sup>a</sup> ± 2.40	78.20 <sup>a</sup> ± 3.19	75.40 <sup>a</sup> ± 2.78
Sperm head abnormality (%)	2.20 <sup>a</sup> ± 0.58	2.40 <sup>a</sup> ± 0.59	2.80 <sup>a</sup> ± 0.37	3.00 <sup>a</sup> ± 0.55
Semen pH	7.12 <sup>a</sup> ± 0.05	6.64 <sup>a</sup> ± 0.01	6.82 <sup>a</sup> ± 0.07	7.02 <sup>a</sup> ± 0.09

Values are presented as mean ± SEM. Values across the table with similar superscripts are not significantly different at 5% based on ANOVA



**Plate 1. Effect of *Ipomoea batatas* tuber on testicular integrity of albino rats**

S1=Primary spermatocyte, S2=Secondary spermatocytes, S3=Spermatid, S4=Spermatozoa, SA=Spermatogonia A, SB=Spermatogonia B, BM=Basement membrane and L=Lumen.

**Plate 1A:** testicular section of the control group indicating prominent seminiferous tubules of various sizes with intact basement membranes containing spermatogonia at various stages of maturation. There was absence of pathology.

**Plate 1B:** testicular section of animals in group B showing prominent seminiferous tubules of various sizes and shapes with distinct basement membrane containing spermatogonia at various level of maturation. No toxicity is observed.

**Plate 1C:** testicular section of group C rats showing prominent seminiferous tubule also containing spermatogonia of 3 to 5 layers thick with distinct cellular outline and prominent basophilic nuclei while the lumen contained spermatozoa. No pathology was observed.

**Plate 1D:** testicular section of group D rats showing seminiferous tubules of various size and shape with prominent basement membrane. The tubules contained spermatogonia at various levels of maturation and the cells have regular cellular outline with round to oval basophilic nuclei. No pathology was also seen.

tuber extract did not interfere with the testicular integrity. This also might have accounted for the non-significant effect of the extract on the parameters studied in line with Ezzat and el – Gohary [21], Mruk and Cheng [22].

## 5. CONCLUSION

The findings of the study revealed that *Ipomoea batatas* tuber extract does not have any significant effect on sperm profile and testicular integrity of male albino rats as mammalian

models. It therefore implies that the consumption of the tuber has no adverse impact on male fertility.

## COMPETING INTERESTS

Authors have declared that no competing interests exist.

## REFERENCES

1. Austin DF, Islam M, Yamakawa O. Anthocyanin composition in sweet potato (*Ipomoea batatas* L.) leaves. *Bioscience, Biotechnology and Biochemistry*. 2006;66: 2483-2486.
2. Woolfe JA. Sweet potato; an untapped food resource. Cambridge: Cambridge University Press; 1992.
3. Udoh F, Udoh P, Umoh E. Effect of *Ipomoea batatas* leaf extract on the thyroid gonadal axis of male Wistar rats. *Sciences*. 2010;7:78–84.
4. Purseglove JW. Tropical Crops. Dicotyledons Longman's scientific and Technical. New York: John Wiley & Sons Inc.; 1991.
5. Bjorndahl L, Soderlund I, Kvist U. Evaluation of the one-step eosin-nigrosin staining technique for human sperm vitality assessment. *Human Reproduction*. 2003;18:813-816.
6. Ekaluo UB, Udokpoh AE, Ikpeme EV, Peter EU. Effect of chloroquine treatment on sperm count and weight of testes in male rats. *Global Journal of Pure and Applied Sciences*. 2008;14:175-177.
7. Ekaluo UB, Ikpeme EV, Udokpoh AE. Sperm head abnormality and mutagenic effects of aspirin, paracetamol and Caffeine containing analgesics in rats. *The Internet Journal of Toxicology*. 2009;7:1-9.
8. Huaman ZA synopsis of *Ipomoea* (Convolvulaceae) in the Americas. *Taxon*. 1996;45:3-38.
9. Duke J, Wain K. Medicinal plant of the World, Vol. 3 Computer index with more than 85,000 entries. Plant genetics and germplasm Institute. Agriculture Research service, Beltsville, Maryland. 2008;231-239.
10. Luo J, Kong L. Study on flavonoids from leaf of *Ipomoea batatas*. *Nutrition*. 2005;30:516-518.
11. Wagner H. The chemistry of resin glycosides of the convolvulaceae family, in: Bendz G, Santesson Journals (eds.), Medicinal and Natural Sciences, Chemistry in Botanical Classification, Academic Press, New York. 2003;235-240.
12. Ludvik B, Pancini G. Efficacy of *Ipomoea batatas* (Caiapo) on diabetes control in type 2 diabetic subjects treated with diet. *Diabetes Care*. 2004;25:239-240.
13. Pereda-Miranda R, Bah M. Biodynamic constituents in the Mexican morning glory: Purgative remedies transcending boundaries. *Curr. Top Med. Chem*. 2003;3: 111–131.
14. Adienbo OM, Wodu CO. Fertility-enhancing potentials of *Ipomoea batatas* (sweet potato) in male albino Wistar rats. *European Journal of Biomedical and Pharmaceutical Sciences*. 2015;2(3):1197-1202.
15. Ikpeme EV, Udensi O, Ekaluo UB, Efieneokwu N. Biological response of male wistar rats to crude extracts of *Ficus exasperate* (VAHL). *International Journal of Current Research*. 2010;7:9-13.
16. Knudson PB. Hypothyroidism in adults: Variable clinical presentation and approaches to diagnosis. *J. Am. Board Fam. Pract*. 1995;8:109-113.
17. Krassas GE, Pontikides N. Male reproductive function in relation with thyroid alterations. *Clin. Endocrinol*. 2004;65(4):446-452.
18. Lohiya NK, Boomi M, Goyal S, Ansari AS. Sperm Motility inhibitory effect of the benzene chromatographic fraction of the chloroform extract of the seeds of *Carica papaya* in Langur monkey, *Presbytis entellus entellus*. *Asian J. Androl*. 2008;10(2):298-306.
19. Mann T. Secretory function of the prostate, seminal vesicle and other male accessory organs of reproduction. *Journal of Reproduction and Fertility*. 1974;37:179–188.
20. Yoshida M, Kitani T, Takenaka A, Kudoh K, Katsuda SI, Taya K. Lack of effect of oxolinic acid on spermatogenesis in young adult and aged Wistar rats. *Food Chemistry and Toxicology*. 2002;40:1815–1825.
21. Ezzat AR, el – Gohary ZM. Hormonal and histological effects of chronic caffeine

- administration on pituitary – gonadal and pituitary – adrenocortical axis in male rabbits. *Functional Development and Morphology*. 1994;4:45–50.
22. Mruk DD, Chen CY. Sertoli – sertoli and sertoli – germ interaction and their significance in germ cell movement in the seminiferous epithelium during spermatogenesis. *Endocrine Reviews*. 2004;25:747–806.

---

© 2017 Ekpo et al.; This is an Open Access article distributed under the terms of the Creative Commons Attribution License (<http://creativecommons.org/licenses/by/4.0>), which permits unrestricted use, distribution, and reproduction in any medium, provided the original work is properly cited.

*Peer-review history:*  
*The peer review history for this paper can be accessed here:*  
<http://sciencedomain.org/review-history/20620>